

# WELCOME

# TO



This is an Education Platform

We provide Free PDF Notes and Videos Classes for Pharmacy Students

Web Site <http://www.fdspharmacy.in/>

You tube <https://www.youtube.com/channel/UC77iEsiuZolU4pB8WAJIR5Q>

What app <https://chat.whatsapp.com/IzSgXtFEvhS4LN5xhUgq5z>


Telegram <https://t.me/+cvxm17xSloA4MjVI>

Face book <https://www.facebook.com/Fdspharmacy-105764311994440/>

E-mail [fdspharmacyinfo@gmail.com](mailto:fdspharmacyinfo@gmail.com)

**Diploma in Pharmacy 1<sup>st</sup> Year  
Human Anatomy and Physiology  
Chapter 11 : Nervous System**

<b>Topics</b>	<b>Page No</b>
<b>Nervous System</b>	<b>3</b>
<b>CENTRAL SYSTEM NERVOUS</b>	<b>4</b>
<b>PERIPHERAL NERVOUS SYSTEM (PNS)</b>	<b>8</b>



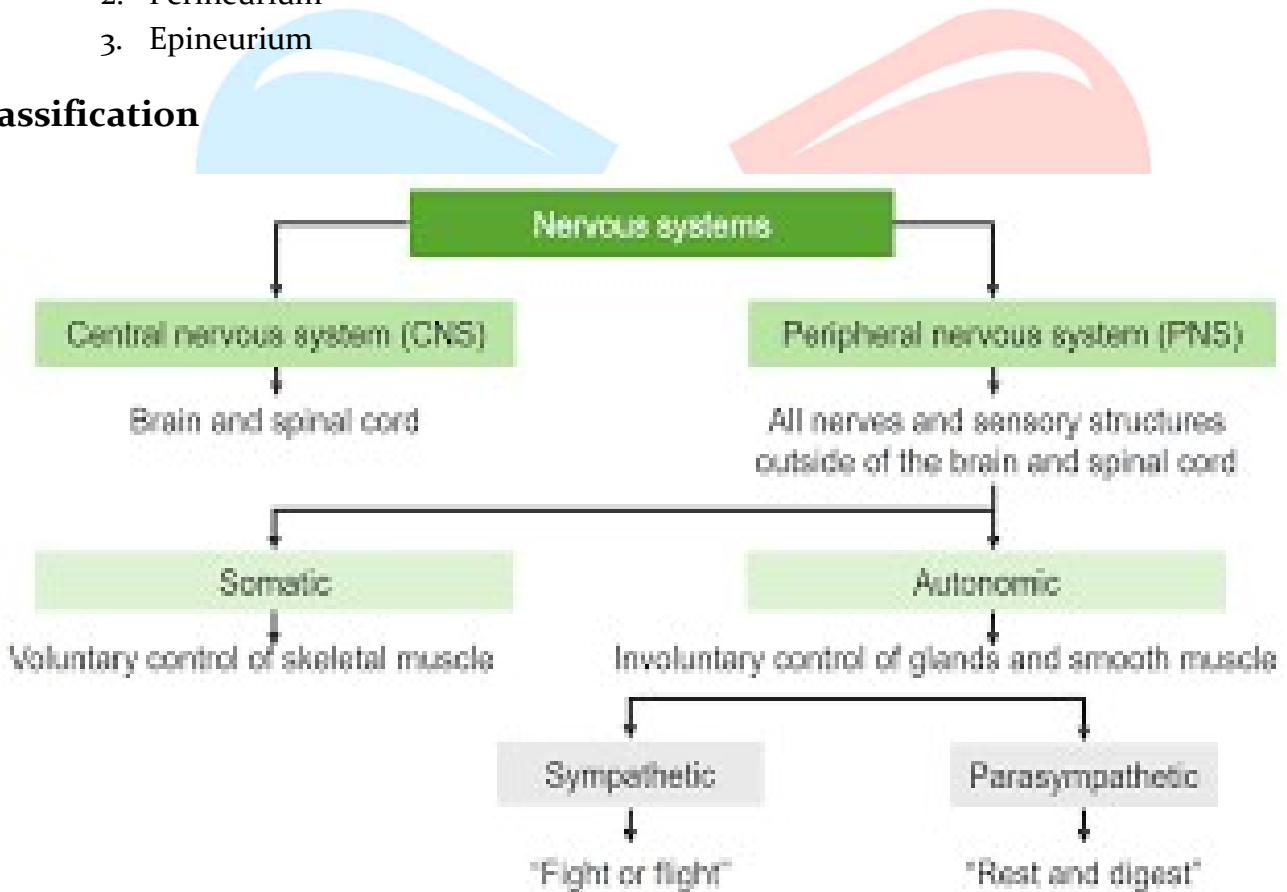
# HUMAN ANATOMY AND PHYSIOLOGY

## Chapter 11

### Nervous System

- Nervous System is a highly advanced network of specialised cells called neurons.
- With the help of millions of neurons, nervous system coordinates the body functions and transmits signals between the different body parts.
- A single nerve is a collection of various neurons. These bundles of neurons are covered by a protective layer of connective tissue; and this layer can be divided into
  1. Endoneurium
  2. Perineurium
  3. Epineurium

#### Classification



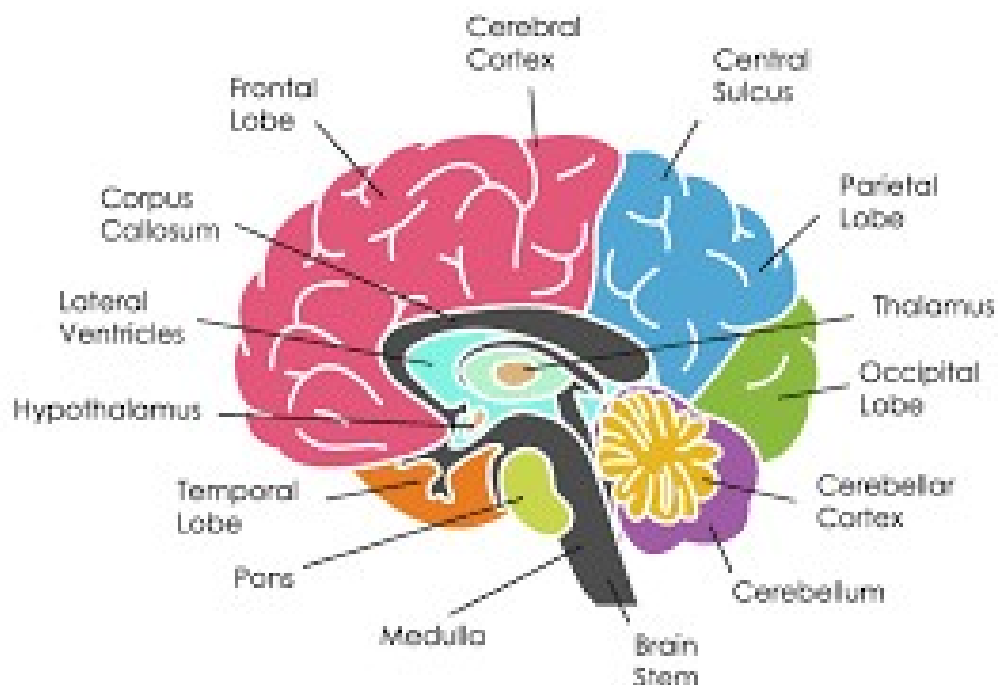
- CNS is the main control centre of the whole system.
- All external and internal stimuli pass to the CNS by means of sense organs and receptors.
- CNS interprets these stimuli and if necessary, response to them ( e.g., moving away from fire, etc.)
- The PNS forms the second major part of the nervous system.
- The PNS is further subdivided into many smaller units.
- It comprises of all nerves connecting the brain and spinal cord to the sensory receptors, muscles, and glands.

# CENTRAL SYSTEM NERVOUS

- Central Nervous System (CNS) consists of the brain (in the cranial cavity) and the spinal cord (in the vertebral column).
- It is safely contained within the skull and vertebral canal of the spine.
- The neural tube inside the embryo develops into a nervous system.
- The neural tube has three expansions at its head end, which arise because of unequal growth rates.
- These expansions take the form of forebrain, midbrain, and hindbrain:
  1. Fore brain: i) Cerebral hemispheres ii) Basal ganglia iii) Thalamus iv) Hypothalamus
  2. Midbrain: i) Tectum ii) Cerebral peduncles iii) Tegmentum
  3. Hindbrain : i) Cerebellum ii) Pons iii) Medulla

## Brain and its Parts

- Brain is a very complex organ, forming the centre of the nervous system.
- It is enclosed in a bony structure termed as cranium.
- The general structure of human brain resembles that of other mammals, except in size.
- The human brain is three times larger in size than the brain of a typical mammal with a comparable body size.
- Cerebral cortex (the major portion of the brain) consists of neural tissue arranged in a convoluted layer, which covers the surface of the forebrain. The frontal lobes of the brain are specifically, expanded and are responsible for carrying out functions like self-control, planning, reasoning, and abstract thought.
- The average weight of brain in an adult man is about 1600gm (3.5 pounds), while in adult female it is 1450gm.
- However, in terms of size, the brain of a male and female are equal.



## Parts of Brain

Brain is enclosed in the cranial cavity It makes up around 1/50th the weight of the body.

The adult brain is composed of the following 4 major parts

- 1) Cerebrum
- 2) Brain stem
  - i) Medulla oblongata
  - ii) Pons
  - iii) Midbrain
- 3) Cerebellum
- 4) Diencephalon

### 1) Cerebrum

- ◆ The brain stem joins the spinal cord and is made up of medulla oblongata, pons, and midbrain.
- ◆ Cerebellum is located posterior to the brain stem; diencephalon comprising of thalamus, hypothalamus, and epithalamus; and is located superior to the brain stem; and cerebrum (the largest part of the brain) lies on the diencephalon and brain stem.

### Lobes of Cerebrum

Each of the two cerebral hemispheres is divided into lobes which are named after the cranial bones comprising them:

- 1) Frontal lobe,
- 2) Parietal lobe,
- 3) Temporal lobe, and
- 4) Occipital lobe

Deep sulcus (fissures) mark the boundaries of the cerebral lobes and are divided into central, lateral, and parieto occipital sulci.

Functions of Cerebrum

Each hemisphere of the cerebrum performs the following functions:

- a. It is responsible for controlling all the voluntary activities.
- b. It receives and processes information pertaining to sensory stimuli.
- c. It is associated with higher brain functions like will, memory, intelligence, reasoning, and learning.
- d. Three different types of activities related to cerebral cortex are:
  - i. Mental activities related to memory, intelligence, thinking, and reasoning, sense of responsibility, moral sense, and learning.
  - ii. Sensory perception related to perception of sensory stimuli including pain, temperature, touch, sight, hearing, taste, and smell.
  - iii. Initiation and control over contraction of voluntary muscles.

### Medulla Oblongata

- Medulla oblongata (2.5cm long) is the lower half of the brain stem, which continues with the spinal cord.
- The upper part of the brain stem is continuous with the pons.
- Medulla oblongata is situated within the cranium, just above the foramen magnum.

- Central fissures mark the anterior and posterior surfaces of the medulla oblongata.
- The outer part is made up of white matter and the inner part is made up of grey matter.
- The white matter passes between the brain and the spinal cord.

### **Medulla oblongata performs the following function**

- 1) The rate and force of cardiac contraction is controlled by the cardiovascular centre with in medulla.
- 2) The rate and depth of respiration is controlled by the respiratory centre. Contraction of the diaphragm and intercostal muscles is stimulated by nerve impulses traversing from the respiratory centre to the phrenic and intercostal nerves. As a result, inspiration is initiated.

### **Pons**

- ◆ Pons is a part of brain stem located above the medulla and below the midbrain.
- ◆ The cerebellum lies posterior to the pons.
- ◆ It primarily comprises of nerve fibres forming a bridge between the two cerebral hemispheres.
- ◆ It also consists of fibres traversing between the higher levels of brain and spinal cord.
- ◆ Groups of cells form relay stations within the pons, some of which are even associated with cranial nerves.

### **Pons performs the following functions:**

- 1) Accessory breathing centres are present within the pons:
  - i) Inspiratory centre is provided by the apneustic centre, and
  - ii) Inspiratory centre is inhibited by the pneumotaxic centre.
- 2) Pons forms a centre for motor relay:
  - 1) Synapsis of descending motor nerves frequently occurs within the pons, and
  - ii) Any injury to the pons results in insufficiency in activities controlled by the motor areas (e.g., paralysis)

### **Midbrain**

- ◆ The midbrain (or mesencephalon) comprises of tracts and nuclei.
- ◆ It divided into the tectum (dorsal part) and the peduncle (ventral part). It gives way to the cerebral aqueduct.

### **Function of Midbrain**

- Significant functions like eye movement and other functions of the Visual and auditory systems are controlled by the midbrain.
- Body movements are controlled by the red nucleus and the substantia nigra (parts of the midbrain).
- Since neurons producing dopamine are located in the substantia nigra, degeneration of these neurons results in Parkinson's disease

### **Cerebellum**

- Cerebellum appears as a distinct structure, forming the lower part of the brain beneath the cerebral hemispheres.

- The cerebellum is separated from the cerebrum by the transverse fissure, a deep groove located along the tentorium cerebelli.

## Functions

- a. Body posture and equilibrium is maintained by the cerebellum. The muscles, joints, eyes, and the ears bring in the sensory input for these functions.
- b. In order to maintain the balance and equilibrium of the body, the cerebellum acts to influence impulses leading to the skeletal muscle contraction. It is responsible for controlling and coordinating the movements of several groups of muscles, resulting in smooth, even, and clear-cut action.
- c. The coordination of voluntary muscular movement is carried out by the cerebellum. Activities of the cerebellum cannot be controlled voluntarily.

## Spinal Cord

- ◆ Spinal cord is the elongated part of the CNS extending from the lower end.
- ◆ It is cylindrical in shape and includes the upper two-thirds of the vertebral canal.
- ◆ It ranges from the level of the upper border of the atlas to either the upper border or the lower border of vertebra.
- ◆ Spinal cord forms the pathway for sensory input to the brain and motor output from the brain.
- ◆ A total of 31 pairs of spinal nerves arise from the spinal cord.
- ◆ Spinal cord and spinal nerves help in the maintenance of homeostasis by providing quick, reflexive responses to many stimuli.
- ◆ The spinal cord and spinal nerves contain neural circuits responsible for rapid reactions towards environmental stimuli.
- ◆ For example, holding hot object will immediately relax the grasping muscles and the object falls prior to getting consciously aware of the extreme heat.

## Functions

The spinal cord has the following functions:

- 1) Sensory and motor tracts are contained within the white matter of the spinal cord.
- 2) The sensory tracts conduct nerve impulses towards the brain and the motor tracts conduct motor nerve impulses from the brain to the effector organs.
- 3) The grey matter of the spinal cord forms the spot for integration (summing) of Excitatory and Inhibitory Postsynaptic Potentials (EPSPS and IPSPS respectively).
- 4) CNS is connected to the sensory receptors, muscles, and glands all over the body via the spinal nerves and their branches.
- 5) All reflex activities are mediated through spinal cord.

## PERIPHERAL NERVOUS SYSTEM (PNS)

- ◆ The peripheral nervous system includes nerves extending between the CNS and other parts of body (muscles, glands, and sense organs)
- ◆ It mainly acts to control the voluntary function of the body.
- ◆ The peripheral nervous system is further sub-divided into somatic nervous system and autonomic nervous system:
- ◆ The sensory nerve fibres carry different impulses from the sensory end organs to the brain, while the motor nerve fibres convey efferent impulses from the brain to the effector organs, through the spinal cord, e.g., skeletal muscles, smooth muscles, and glands.

The PNS comprises of:

- a. **Sensory Neurons:** They carry information in the form of stimuli from the sensory tissues and receptors to the CNS.
- b. **Motor Neurons:** They carry back the information from the CNS to the effector organs (muscles and glands) for action.
- c. **Somatic Nervous System:** This system controls skeletal muscles and the external sensory organs.
- d. **Autonomic Nervous System:** This system controls involuntary actions of the body by controlling the involuntary muscles like the smooth muscles and the cardiac muscles. It further includes sympathetic and parasympathetic systems.

## AUTONOMIC NERVOUS SYSTEM (ANS)

- ◆ Involuntary functions of the body (e.g, activity of heart muscles, smooth muscles, glands, and muscles) are controlled by the autonomic nervous system.

ANS is further categorised into:

- 1) Sympathetic (thoracolumbar outflow) system, and
- 2) Parasympathetic (craniosacral outflow) system.

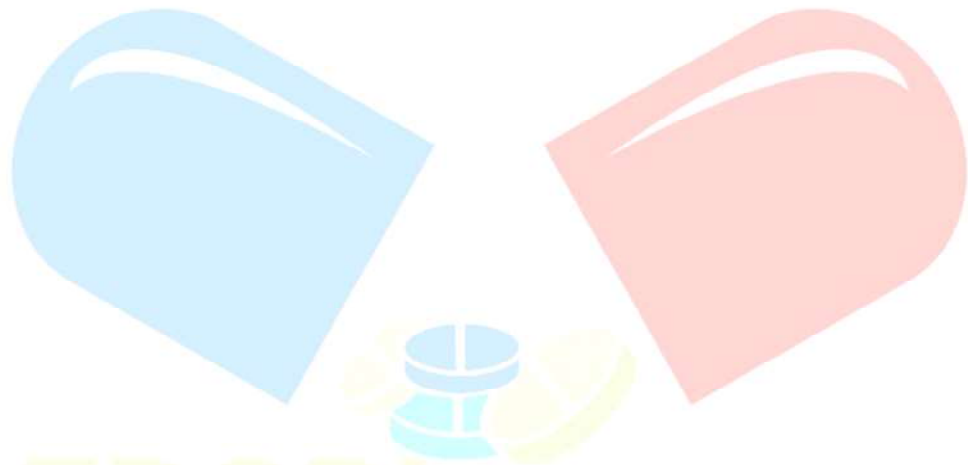
### Sympathetic Nervous System (SNS)

- ◆ Sympathetic nervous system controls physical or emotional stress like stress due to work or exercise, pain, and unfavourable living conditions (like too cold and hot weather), etc.

### Parasympathetic Nervous System (PSNS)

- ✓ The preganglionic fibres of the parasympathetic nervous system arise from the cell bodies of the CNS. They originate from the nuclei of the third, seventh, ninth, and tenth cranial nerves (CN III, VII, IX, and X) and the fourth sacral segments (S<sub>2</sub> to S) of the spinal cord. Hence, the parasympathetic nervous system is said to have the craniosacral outflow.





FDS Pharmacy  
Learn and Educate

THANK YOU

Hello  
Friends  
If You Get Any Help from this  
Notes /Videos  
You Can Pay Your Fees  
Or  
Contribute Some Amount  
To  
Our FDS Pharmacy Family

Name : Amir Khan

