

WELCOME

TO



FDSPharmacy

Learn and Educate

This is an Education Platform

We provide Free PDF Notes and Videos Classes for Pharmacy Students

Web Site <http://www.fdspharmacy.in/>

You tube <https://www.youtube.com/channel/UC77iEsiuZolU4pB8WAJIR5Q>

What app <https://chat.whatsapp.com/IzSgXtFEvhS4LN5xhUgq5z>

Telegram <https://t.me/+cvxm17xSloA4MjVI>

Face book <https://www.facebook.com/Fdspharmacy-105764311994440/>

E-mail fdspharmacyinfo@gmail.com

Diploma in Pharmacy 1st Year

Human Anatomy & Physiology

Experiment

To perform the microscopic examination of the given cardiac muscle tissue slide.

Aim:

To perform the microscopic examination of the given cardiac muscle tissue slide.

Reference :

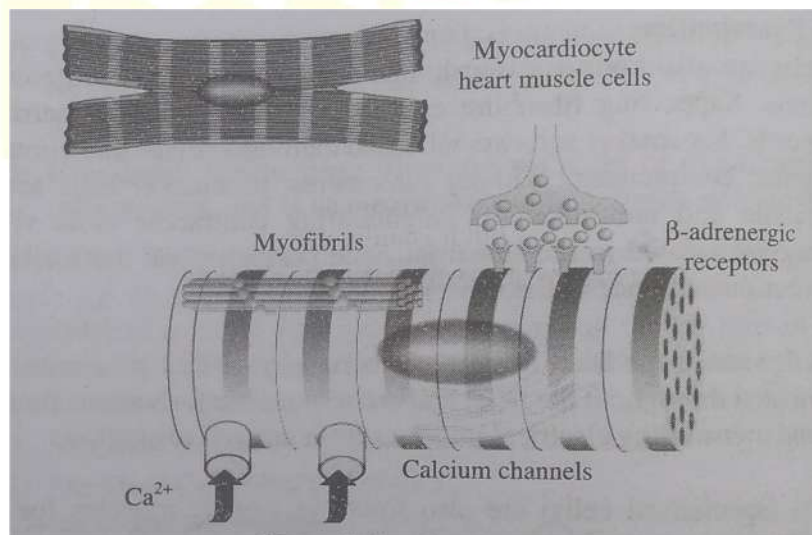
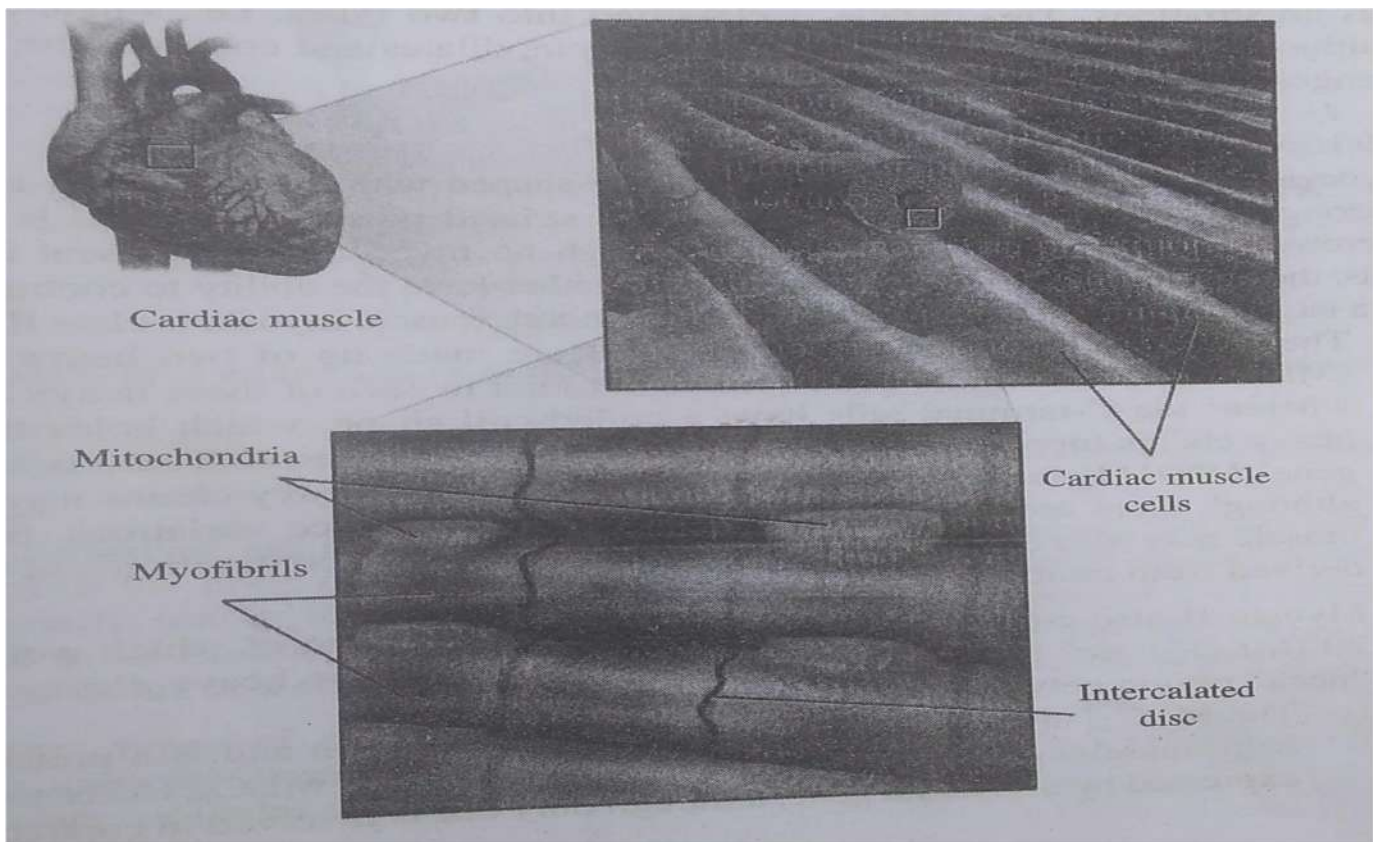
Dr. Gupta G.D , Dr. Sharma Shailesh , Dr. Sharma Rahul Kumar ,
“Practical Manual of Human Anatomy and Physiology” Published by Nirali
Prakashan , Pg.No 11- 14

Theory :

- Cardiac muscle, commonly known as heart muscle or myocardium, is one of three forms of muscle tissue found in vertebrates.
- The other two are skeletal and smooth muscle.
- It is an involuntary, striated muscle that makes up the majority of the heart's wall tissue.
- Between the pericardium (outer layer of the heart wall) and the endocardium (inner layer of the heart wall), the cardiac muscle (myocardium) creates a thick middle layer.
- This layer is supplied blood through the coronary circulation.
- Individual cardiac muscle cells are connected together by intercalated discs, and the extracellular matrix is made up of collagen fibres and other components.

Microscopic Examination

- Cardiac muscles are also known as Cardiomyocytes that are contractile cells of the heart muscle. Supporting fibroblast cells form an extracellular matrix that surrounds the cells. Pacemaker cells are modified cardiomyocytes that control the rhythm of cardiac contractions. Without sarcomeres, pacemaker cells are only weakly contractile and are linked to neighbouring contractile cells via gap junctions. They are located in the sinoatrial node positioned on the wall of the right atrium, near the entrance of the superior vena cava.
- The impulses that cause the heart to beat are carried by cardiac pacemaker cells. They are distributed throughout the heart and are responsible for various functions, like creating and transmitting electrical impulses from one cell to another.
- Purkinje fibres (specialised cells) are also found in cardiac muscles for quick transmission of electrical signals. Coronary arteries for providing nutrients to the muscle cells, and veins and a capillary network for removing waste products are also found in cardiac muscle.
- The cardiac muscles are the contracting cells that allow the heart to pump the blood. To successfully pump blood from the heart, each cardiomyocyte must contract by coordinating with its neighbouring cells; this is known as a functional syncytium. In case, this coordination breaks down, the heart may not pump blood at all. For example, this condition may arise during irregular cardiac rhythms like ventricular fibrillation.



Cardiac muscles

Result:

The microscopic examination of the given cardiac muscle tissue slide was performed.

Hello

Friends

If you Get Any Help From This Notes /

Videos

Next You Turn To Help Us

Please Contribute Some Amount

To Our

FDSPharmacy Team

Phone pe 6398439940

Paytm 6398439940

Google Pay 6398439940



Amir Khan

Thank You

Keep Supporting