

WELCOME

TO



FDSPharmacy

Learn and Educate

This is an Education Platform

We provide Free PDF Notes and Videos Classes for Pharmacy Students

Web Site <http://www.fdspharmacy.in/>

You tube <https://www.youtube.com/channel/UC77iEsiuZolU4pB8WAJIR5Q>

What app <https://chat.whatsapp.com/IzSgXtFEvhS4LN5xhUgq5z>

Telegram <https://t.me/+cvxm17xSloA4MjVI>

Face book <https://www.facebook.com/Fdspharmacy-105764311994440/>

E-mail fdspharmacyinfo@gmail.com

Diploma in Pharmacy 1st Year

Human Anatomy & Physiology

Experiment

To perform the microscopic examination of the given epithelial tissue slide.

Aim:

To perform the microscopic examination of the given epithelial tissue slide.

Reference :

Dr. Gupta G.D , Dr. Sharma Shailesh , Dr. Sharma Rahul Kumar ,
“Practical Manual of Human Anatomy and Physiology” Published by Nirali
Prakashan , Pg.No 6 - 10

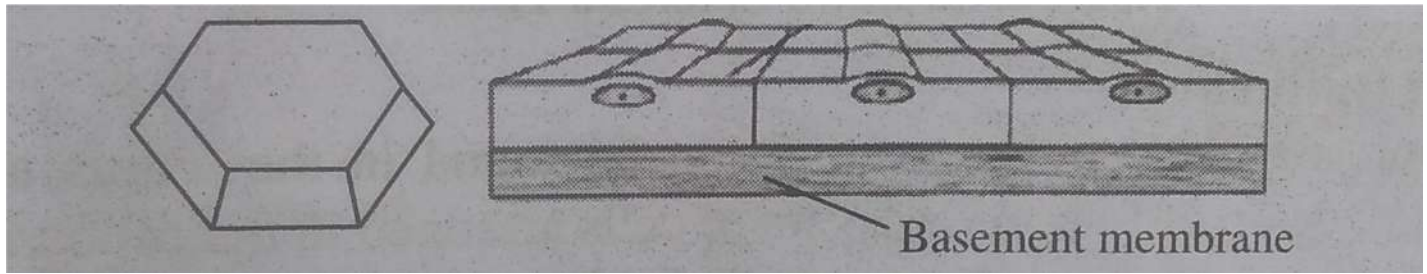
Theory :

Tissues are a group of cells having the same origin, similar shape, and a common generalised function.

Epithelial Tissue

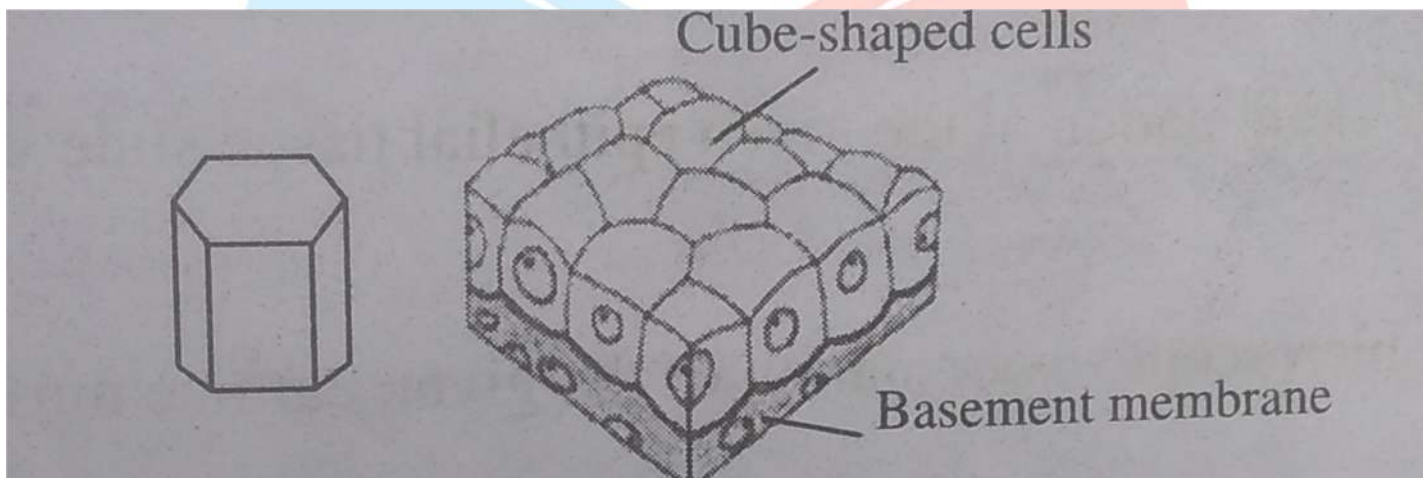
- Epithelial tissues are the coating or lining of the body surface. They perform important body functions like protection, elimination, glandular secretion, and absorption. The epithelial cells contain less amount of extracellular fluid, yet they are structured on a basement membrane. The epithelium is further divided into the following categories :

- 1) **Simple Epithelium** : It consists of a single layer of cells and is classified into:
 - i. **Squamous (or Pavement) Epithelium** : This type of epithelium covers the alveoli of the lungs, pericardial, pleural, and peritoneal cavities, and is made up of flat cells arranged edge to edge like a mosaic.



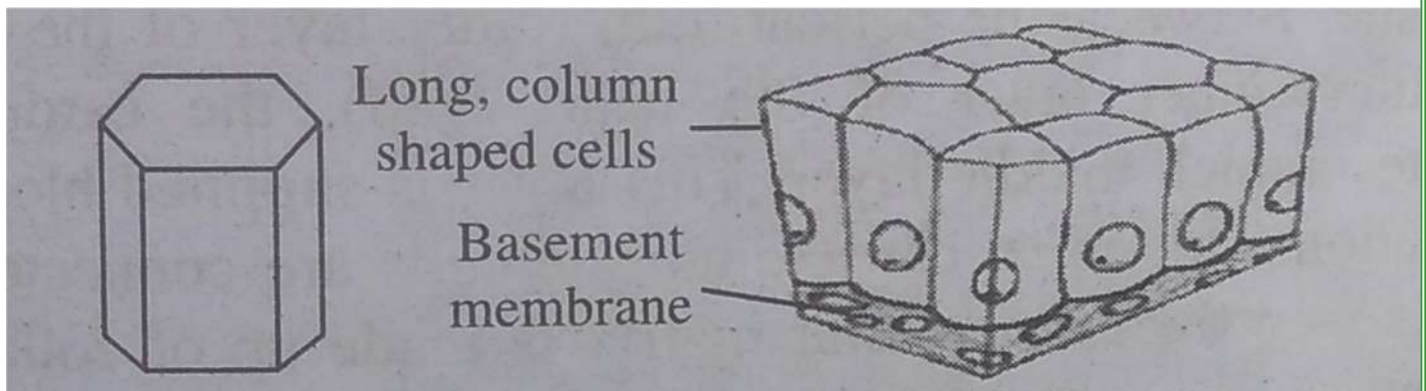
Squamous (or Pavement) Epithelium

- ii. **Cuboidal Epithelium** : The cells in this type of epithelium are cubical and organised over a basement membrane. It is present in the kidney's distal convoluted tubules.



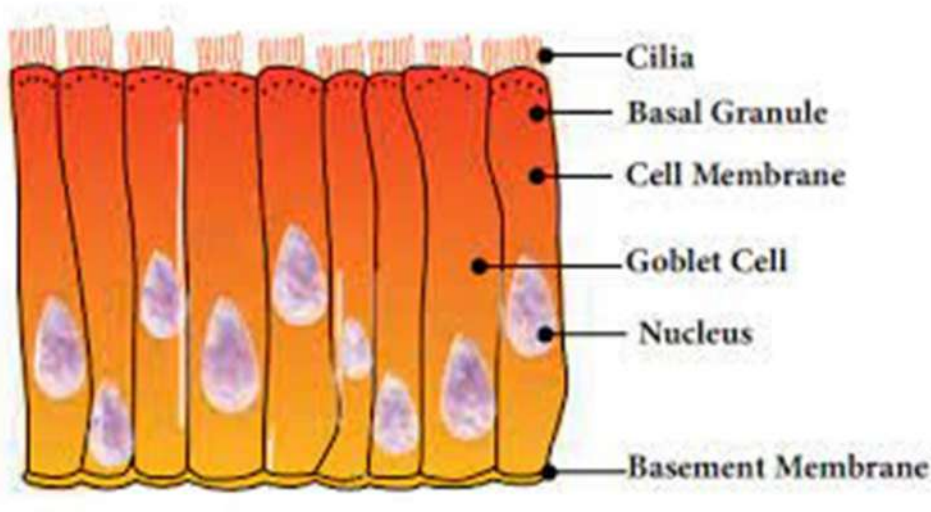
Cuboidal Epithelium

- iii. **Columnar Epithelium** : This type of epithelium is made up of tall, pillar-like cells that are placed on a basement membrane. It is present in the lungs and gland ducts.

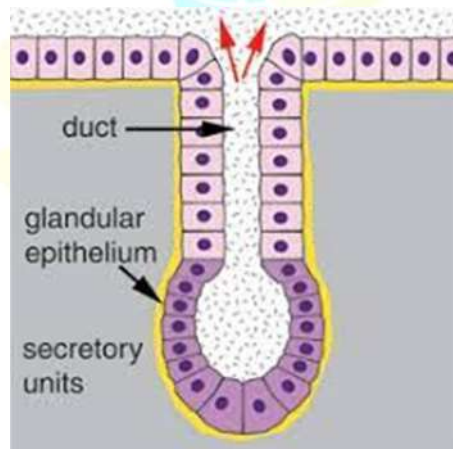


Columnar Epithelium

- iv. **Ciliated Epithelium** : This epithelium has cuboidal or columnar cells and can be found in the free border of cells, such as those that line the trachea.

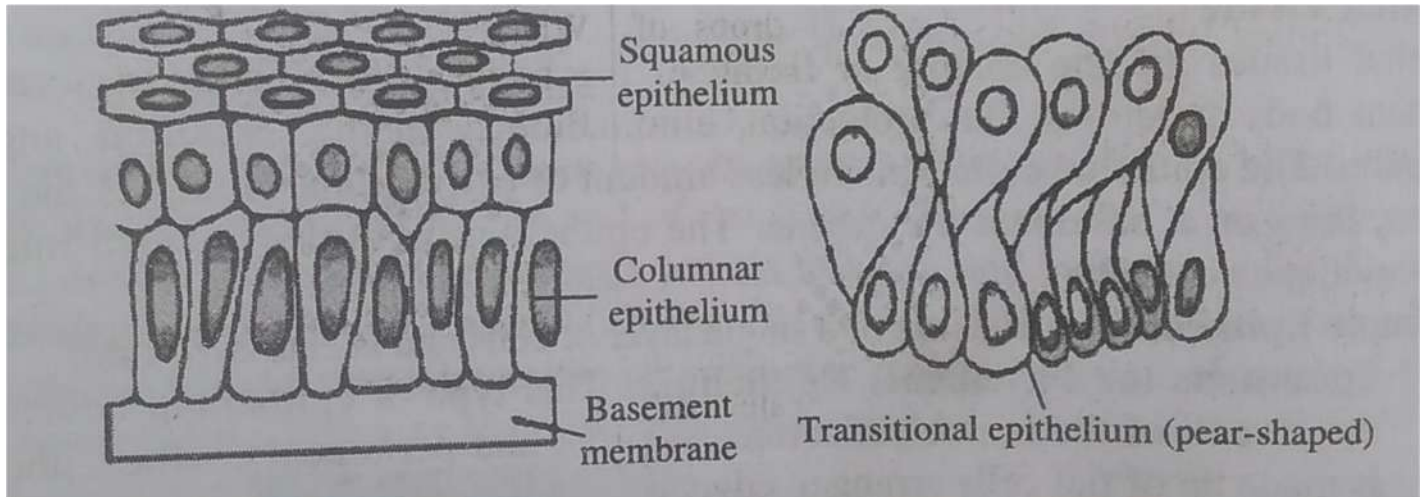


- v. **Glandular Epithelium** : They are made up of cylindrical or columnar cells and is found in secretory glands like salivary and breast glands.



2) Stratified Epithelium : It is also known as compound epithelium and is made up of many layers of cells. It can be found on surfaces that have experienced a lot of wear and tear, depending on the type of cells present. The stratified epithelium is further divided into the following categories:

- i) Stratified Squamous Epithelium
- ii) Stratified Cuboidal Epithelium
- iii) Stratified Columnar Epithelium.



Transitional Epithelium

It is a type of stratified epithelium that can be found in the uterus and urinary bladder. It is made up of four to six layers of cells arranged in the following order:

- 1) The tower basal row is made of cuboidal cells.
- 2) Intermediate layer is made of long and polyhedral cells.
- 3) Superficial layer is made of larger and flattened cells.

Result:

The microscopic examination of the given epithelial tissue slide was performed.

Hello

Friends

**If you Get Any Help From This Notes /
Videos**

Next You Turn To Help Us

Please Contribute Some Amount

To Our

FDSPharmacy Team

Phone pe 6398439940

Paytm 6398439940

Google Pay 6398439940



Amir Khan

Thank You

Keep Supporting