

# WELCOME

# TO



# FDSPharmacy

Learn and Educate

This is an Education Platform

We provide Free PDF Notes and Videos Classes for Pharmacy Students

Web Site <http://www.fdspharmacy.in/>

You tube <https://www.youtube.com/channel/UC77iEsiuZolU4pB8WAJIR5Q>

What app <https://chat.whatsapp.com/IzSgXtFEvhS4LN5xhUgq5z>

Telegram <https://t.me/+cvxm17xSloA4MjVI>

Face book <https://www.facebook.com/Fdspharmacy-105764311994440/>

E-mail [fdspharmacyinfo@gmail.com](mailto:fdspharmacyinfo@gmail.com)

# Diploma in Pharmacy 1<sup>st</sup> Year

## Human Anatomy & Physiology

### Experiment

To study the bones of upper limbs

#### Aim:

To study the bones of upper limbs.

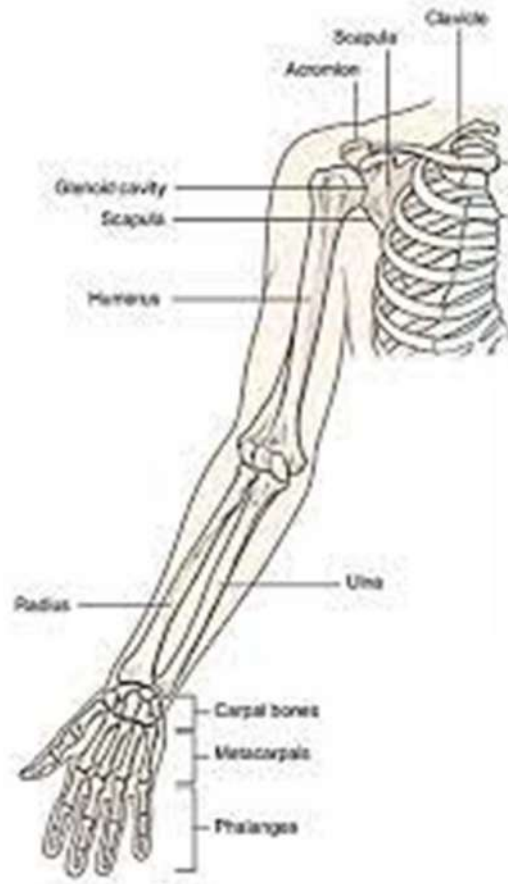
#### Reference :

Dr. Gupta G.D , Dr. Sharma Shailesh , Dr. Sharma Rahul Kumar ,  
“Practical Manual of Human Anatomy and Physiology” Published by Nirali  
Prakashan , Pg.No 43 - 47

#### Theory :

The bones of the upper limbs are:

- 1) **Humerus** : This is the upper arm bone. The shoulder joint is formed by the fits within the glenoid cavity of the scapula. The greater and lesser tubercles are roughened bone projections distal to the head, and between them there is a deep channel, the bicipital channel or intertubercular sulcus, inhabited by one of the biceps muscle's tendons.
- 2) **Ulna and Radius**: The forearms are made up of two bones. When the arm is in the anatomical posture, i.e., with the palm of the hand facing forward, the ulna is longer and medial to the radius, and the two bones are parallel. The lower epidermis is identical to the upper epidermis, but it has more trichomes and stomata than the upper epidermis.
- 3) **Carpal (Wrist) Bones**: These are eight carpal bones arranged in two rows of four. From outside inwards, i.e., proximal rows and distal rows. Ligaments hold them in place and allow for a limited degree of movement between them.



- 4) **Metacarpal Bones (Bones of the Hand):** These five bones are located in the palm of the hand. They are numbered from the thumb side inwards. The distal ends articulate with the phalanges, whereas the proximal end articulates with the carpal
- 5) **Phalanges (Finger Bones):** Each finger has three phalanges, while the thumb has two. They have hinge joints that connect them to the metacarpal bones and to each other.

## Result:

The bones of upper limbs were studied